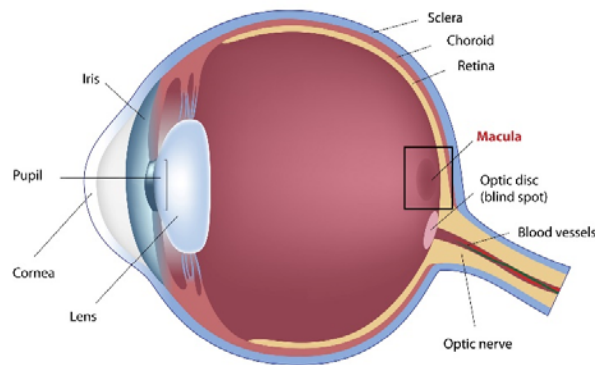


The Homeopathic Treatment of Macular Degeneration

Macular degeneration

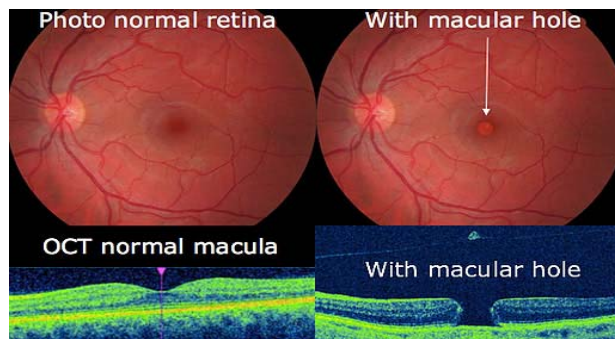
Many homeopaths are reluctant to treat age related macular degeneration for several reasons. First, there is a poor understanding of the pathology and its affect on the visual system. Second is the belief that only a specialist should treat this serious disorder, and lastly is the belief this condition will not respond to homeopathy-it is an incurable state.

Since there is no effective allopathic treatment, why not try homeopathy? The homeopathic treatment of macular degeneration is a unique opportunity for homeopaths. I would like to share my experiences using homeopathy in the treatment of this disorder.



Definition of Age Related Macular Degeneration (ARMD)

Macular degeneration is a pathological condition that occurs in the macular area of the retina. The macula is the area of the retina responsible for central vision or that which gives us the greatest detail in our sight. The pathological changes primarily occur in the choroid (the vascular layer of the eye which lies between the sclera and the retina) and pigmented retinal epithelium (PRE – the layer separates the choroid from the retina). These changes may lead to fluid accumulation, hemorrhage and scar tissue. Loss of central vision occurs, but this rarely produces total blindness because the peripheral vision is preserved. ARMD is found mostly in people over 65. It affects men and women equally. Nearsighted ones, outdoor people, and those that are exposed to UV light from the sun have a greater chance as well.



Symptoms of ARMD

When a patient has ARMD, vision in the center of the visual field gets fainter and fainter until finally there is hardly any way to see objects in the center of the visual field. The first thing most people will notice is a lessening of their sight as they look straight ahead at things, like the printed word, faces or clocks. This may be a dimming, a blurring, or actual "holes" or black spots in the vision. Extreme light sensitivity and poor night vision can also precede ARMD. Light-to-dark adaptation is also apt to be very slow.

Macular degeneration rarely leads to total blindness. Instead, worsening symptoms include a loss of central vision and a diminished ability to see things straight ahead. People with ARMD will rely more and more on peripheral vision. Sometimes, in the early stages, there are holes in the vision, called scotoma. These are areas where you cannot see anything. Many people with ARMD become unable to drive and are eventually declared legally blind.

Types of ARMD

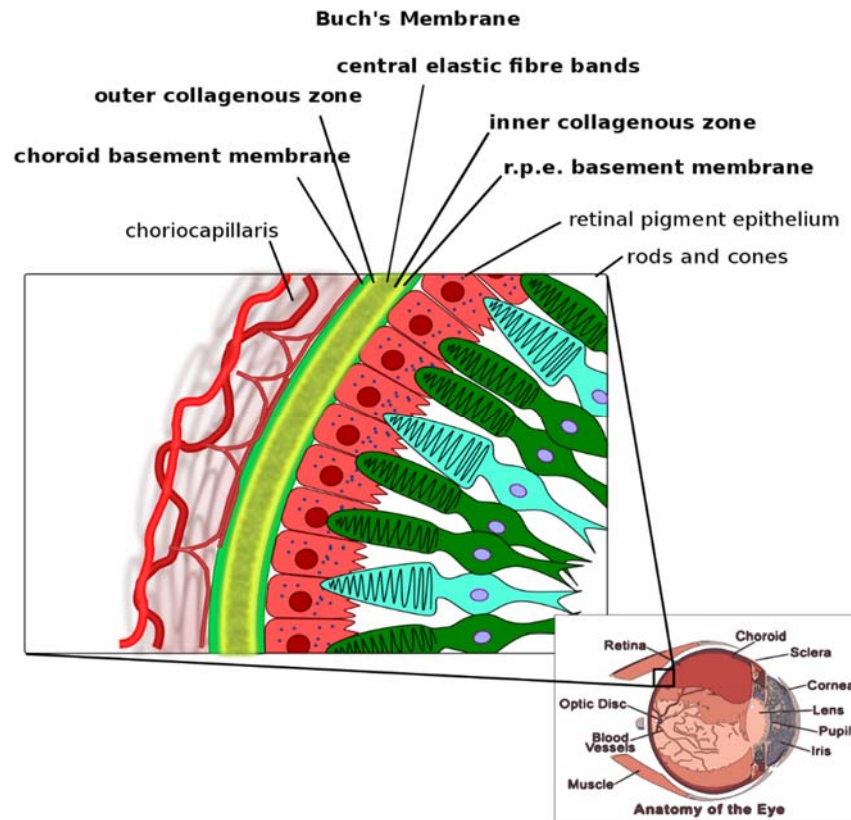
There are two main types of macular degeneration: wet and dry.

The dry, areolar type consists of degeneration of the retinal pigment cells resulting in drusen (see below), and hyper and hypo-pigmented areas in the retina with loss of rods and cones, and generalized atrophy. Dry ARMD, which affects 90% of persons with ARMD, results from a buildup of cellular waste product called drusen or bump, or gland, in the back part of the inner eyeball where the retina and macula are. It refers to the earliest changes that are observed in ARMD. A drusen develops on Bruch's membrane. This occurs when the retinal pigment epithelium becomes overloaded with undigested discs from the cones. This material collects on Bruch's membrane producing thickened areas.

The wet type or exudative type presents as vascular leakage with exudates and a detachment of the retina with loss of vision. In addition, when the retinal pigment epithelium becomes overloaded, the RPE cells begin to degenerate. Debris begins to accumulate at the base of these cells. These cells lose their attachment to Bruch's membrane and fluid begins to accumulate under the cells. Soon there are breaks in Bruch's membrane leading to growth and leakage of blood vessels from the choroid. This leakage and new blood vessel growth into the retina lead to the wet stage of macular degeneration. A few cases have been treated successfully with an argon laser. Diabetics can develop another type of wet MD, resulting from leakage of small blood vessels, accumulating under the retina and thus loss of central vision.

Summary of the types of macular degeneration:

- **Development of Drusen**
- **Dry Stage of Macular Degeneration**
- **Wet stage of Macular Degeneration**
- **Degeneration of Retinal Pigment Epithelial Cells**
- **Absorption of Blood with the Development of Scar Tissue**
- **Breaks in Bruch's Membrane Leading to Growth and Leakage of Blood Vessels**



Traditional treatment

Many studies that have shown that the antioxidants, Vitamins A, C, E, Zinc and Selenium can retard the progression of this disorder. One of the treatments for **wet ARMD** uses laser surgery to cauterize the leaky blood vessels. This measure may preserve more vision in the long run, but usually results in worse vision in the short run because healthy tissue is almost always destroyed along with the diseased vessels.

Homeopathic approach

Macular degeneration can be treated homeopathically just like any other disease state of the body. The constitutional approach works best, the goal is to find the remedy for the totality of the case. When that is not clear or a constitutional treatment is not accepted, a lesional approach can be used.

Rubrics (set of rules) for Macular degeneration:

INFLAMMATION – Choroid

EYE – INFLAMMATION – Chorio-retinitis

EYE – ATROPHY – CHORIOD, Atrophic spots

EYE – INFLAMMATION – Retina – pigmented

EYE – INFLAMMATION – Retina – punctata albescens

EYE – INFLAMMATION – Retina – syphilitic

EYE – INFLAMMATION – Retina

VISION – DIM VISION – FOGGY

VISION – LOSS OF VISION – vanishing of sight

VISION – LOSS OF VISION – colors, for

VISION – SCOTOMA VISION – SCOTOMA – central

Constitutional approach

Miasms

I first try to uncover the miasm stages so as to limit the remedies under consideration. The wet type of degeneration represents the sycotic miasm. The dry type represents the syphilitic miasm.

Psoric Stage – This is the earliest presentation with minimal pigmentary changes and a loss of the foveal light reflex. The foveal light reflex is produced when healthy cones reflect the light, which enters the eye. As the cells become weakened with age and disease, they lose the ability to reflect light.

Sycotic Stage - There is a hyperproliferation of tissue in the macular area. This can manifest as excessive pigment which has the appearance of dark pepper like specks in the macular area. Another presentation can be that of drusen. These drusen cause a weakening of the retina and can lead to death of the photoreceptive cells. This weakness can also cause tiny blood vessels to grow into the retina. These vessels can leak fluid or bleed and cause a sudden loss of vision.

Syphilitic Stage – There is more destruction of tissue with atrophy and destruction of the retina.

Description of lesion

Characteristics of the macula can be very useful in remedy differentiation. Is the lesion wet or dry? Is there hyperpigmentation or hypopigmentation? What color is the exudate? Yellow, white, or orange? Is there blood present? What color is the blood? As an ophthalmologist I have the unique ability to observe the changes inside the eye and use these physical findings to help select the remedy. Also ask the patient to bring in retinal photos of the macular degeneration to study these characteristic features.

Rubrics that I have found to be helpful in treating macular degeneration are:

SKIN: CICATRICES, DISCOLORATION, EXCRESCENCES, ERUPTIONS, FRECKLES, INFLAMMATION, WARTS.

GENERALS: ARTERIOSCLEROSIS, ATROPHY, HEMORRHAGE, INDURATIONS, INFLAMMATION, TUMORS, STASIS of the venous system.

Remedies that have an affinity to the eye:

- Retinal Atrophy

- o Carboneum sulphuratum
- o Cina maritima
- o Haliaeetus leucocephalus
- o Kalium chloricum
- o Phosphorous
- o Santoninum
- o Sanicula
- o Tabacum
- o Vanadium

- Choroidal Atrophy

- o Cina maritima
- o Kalium chloricum
- o Kali iodatum
- o Santoninum
- o Veratrum viride

Tissue salts

Tissue salts can also be useful in the treatment of macular degeneration. The following salts have been helpful in the treatment of ARMD:

- *Calc flourica 8X* – The tissue strengthener
- *Calc phosphorica 6X* – The cell builder
- *Kali phosphorica 6X* – Nerve nutrient
- *Natrum muriaticum 6X* – The fluid distributor.

Dryness or excessive moisture anywhere in the body. Helpful in cases of wet macular degeneration:

- *Carboneum sulphuratum* – Success in early ARMD was by using Carboneum sulphuratum, using 30C everyday and some have seen resolution of drusen and pigmentary changes.
- *Secale* – Dr. Johann A. Miller has had good success with Secale in the treatment of macular degeneration. Secale is used in low potency when the patients have some general signs compatible with Secale such as, being worse from heat and better from cold.
- *Sanicula and Vanadium* – Dr. A. U. Ramakrishnan has used Sanicula in cases of macular degeneration with the symptom of wavy vision. He has also used Vanadium 200C every month for the treatment of macular degeneration.
- *Sarcode – Human retina 5C*: Max Tetau has reported the affects of 5C, 7C and 9C sarcodes on the tissue that was prepared. 5C Stimulates activity of the tissue from which it was derived. 7C normalizes tissue activity and 9C suppresses tissue activity. Human retina 5C has also been used successfully in stimulating the activity of the failing macula.

Case 1

76 year old female. Prominent look of suffering on her face during the interview. Recent episode of a hypertensive crisis with a reading of 220/146, she is very anxious about getting her vision back and has had over ten laser treatments in both eyes. She is worried about the future and what will happen. She needs more information. She needs the information so she can do whatever will help her. She has to be sold on this approach; she is a skeptical person. She sleeps with the light on all night. She was robbed as a child and has a fear of robbers. She is afraid that a man will come up through a trap door. Her parents' home was large with fourteen rooms. She and her sister would take turns staying up at night. She has a fear that someone is in the room. She is on guard all the time. She sleeps facing the door on her left side. She also has small lady's gun which is loaded. She will sleep for a couple of hours and then wake at 2:00 to 3:00 AM. The fears are worse when she is alone. She stayed up all night when her husband was in the hospital. She could solve this problem if she had a dog. The dog would be on guard instead of her.

Physical exam 5/100 right eye, 5/10 left eye Cataracts Central scarring in right eye from laser treatment Retinal pigmentary changes with large drusen (Tumors/Warts) in left eye.

Diagnosis: **ARMD Cataracts Hypertension Anxiety.**

Rubrics

FACE – EXPRESSION – suffering

MIND – FEAR – alone, of being; – ANXIETY – health; about his/her own health; – night

GENERALS – TUMORS

She escapes by reading books about the simple life. Small town, a quiet place, the neighbors visiting each other. She likes the feel of soft clothes. Desires creature comforts. She wants a simple dog, who stays on guard at night. There are many aspects of *Calcarea carbonica* in her story with issues of home-security, enjoying the simple pleasures of life. There is also the fear and anxiety element of Arsenicum album.

Plan: ***Calcarea arsenicosum LM1***

Follow up one year later: It took her 2 months before she started the remedy because she had a strong fears of an aggravation. She feels good. Lots of energy. She can relax easily. She has a lot more energy in her business. She is getting a lot of compliments on her skin since taking the medication. Her fears are greatly improved. She does not have the fear of being robbed. Her fears at night have greatly improved. Happier and more relaxed. Her vision has improved two lines on the chart. Physical Exam: 5/100 in the right eye, 5/10 in the left eye.

Case 2

78 year old female. Chief complaint is macular degeneration, cataracts and a balance problem. She has noticed her vision decreasing since her last eye exam when she was told that she had macular degeneration and cataracts. Vision is very dim and she has trouble reading. The vertigo comes on suddenly and she then goes down like a rock. Room spins from left to right. She is debilitated. She is like a quivering old lady. She is so weak that her arms and legs shake. Twice it happened at 7:00 AM when she woke up from bed. She pulled herself up with great effort. She lives in fear that this attack will come back again when she is under stress. She works as a real estate broker. When she has a stressful conversation she can feel her balance leave her. She feels that the bottom is dropping out of her stomach and she experiences light-headedness. She has also developed ringing in her ears associated with vertigo.

An important aspect of her life was ballroom dancing which she did with great dedication. She is very depressed because now she can't compete. She feels hopeless and withdrawn. Her sexual drive was never very high and she is not in a relationship. She states there is a lot of sexuality in dancing. She enjoys the provocative aspects of the Latin dancing.

Physical exam: 20/300 right eye, 3/100 left eye. Advanced cataracts in both eyes. Myopic degeneration with atrophic changes in her retina.

Diagnosis: **ARMD, Vertigo, Cataracts.**

Rubrics

EYE – CATARACT

VERTIGO – ACCOMPANIED by – staggering; SUDDEN

EAR – NOISES in – ringing

MIND – DANCING

FEMALE GENITALIA/SEX – SEXUAL DESIRE – diminished

In Norton's article "*The Homeopathic Treatment of Incipient Senile Cataract, with Tabulated Results of One Hundred Cases*", *Sepia* is the number one remedy to think of in females with advanced cataracts.

Plan: ***Sepia* LM1**

Eight months follow up: She can read the menu. She's had a seventy percent improvement in her vision. Street signs are becoming clearer – colors are vivid. No more dizziness – stronger and confident walking. No more ringing in her ears. PE – vision is now 20/200 OU.

Case 3

78 year old female. She developed cloudy vision in the left eye. Her vision became very dim and letters began to run together while she was reading. Her biggest difficulty in life has been her relationship with her daughter. "She does not return my letters. She hangs up the phone when I call. My life's biggest disappointment. She has told lies about my husband and I. You know mother, you are a slob. I wanted to cry but I could not cry. How could she be so hurtful? We could go for hours not talking to each other. My daughter would not appreciate anything that I did. I wanted to tell her to 'go to hell' but I did not because I did not want to exacerbate it. I get angry very quickly. A silly little thing will irritate me. I was eating my salad and they brought out the main course. It was cold and I became extremely upset."

Physical exam: Retinal pigment atrophy in the left eye. Vision 10/10 right, 1/70 left eye

Diagnosis: **ARMD Hypertension**

Rubrics

MIND – CONTRADICTION – intolerant of contradiction; ANGER – trifles and violent

CHEST – PALPITATION of heart – anger

VISION – RUN together – letters

Plan: ***Staphysagria* LM1**

Seven months follow up: Peripheral vision is better on left eye – the right she has noticed an overall improvement. Colors are much brighter, she is not getting angry as easily. She called her daughter and had a good meeting. Vision improved 3 lines (1/40) in the left eye, and 10/10 in the right eye.

Dr. Edward Kondrot, MD(H),CCH, a board certified ophthalmologist, is recognized as a pioneer in the use of homeopathy for eye conditions and is director of the Healing the Eye and Wellness Center in Arizona. He is author of "[Healing the Eye the Natural Way: Alternative Medicine and Macular Degeneration](#)", "Microcurrent Stimulation: Miracle Eye Cure", and Homeopathy and Eye Disease (Audio Tape). Visit him at his website at <http://www.homeopathiceye.com>